

NOTICE: This folder or file is part of J. Edgar Hoover's "Official and Confidential (O&C)" Files which were removed from his office after his death and are now kept in the Special File Room to maintain their integrity and to better preserve them. The O&C files are assigned file number 62-116606. They consist of 164 folders or files. This folder or file has been processed for release by the FOIPA Section and is identified as Folder Number 97.

  
#8503R Third Cut



1K-7K, 9K-17K, 19K-31K,  
33K-37K, 40K, & 42K.  
(A1 - A36)





62K



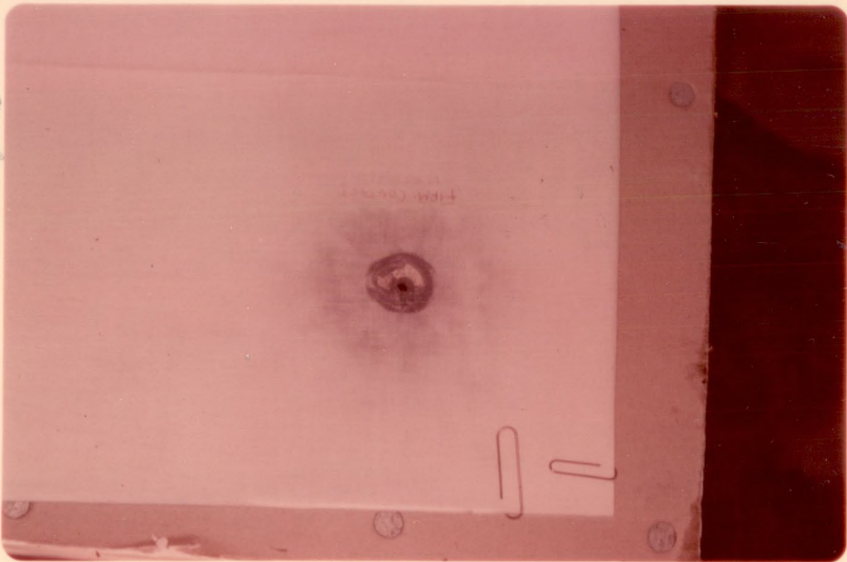
61K



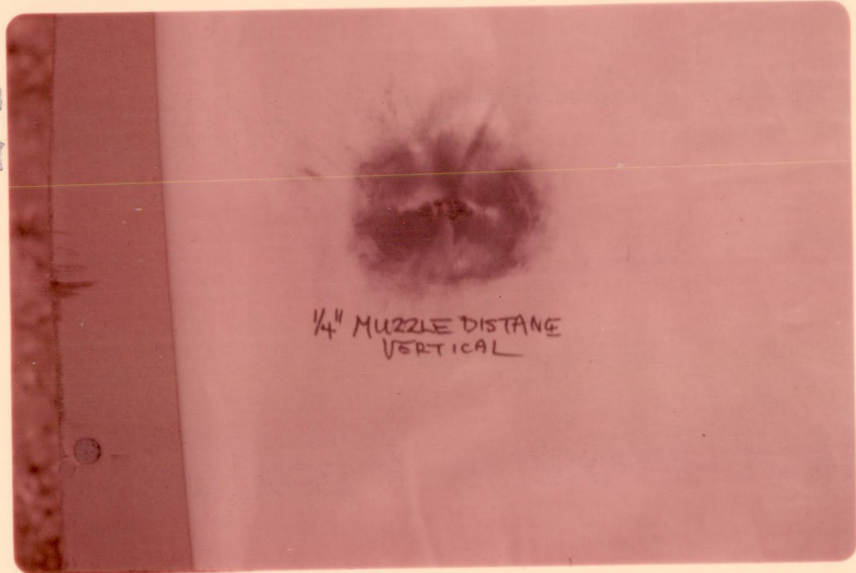60K



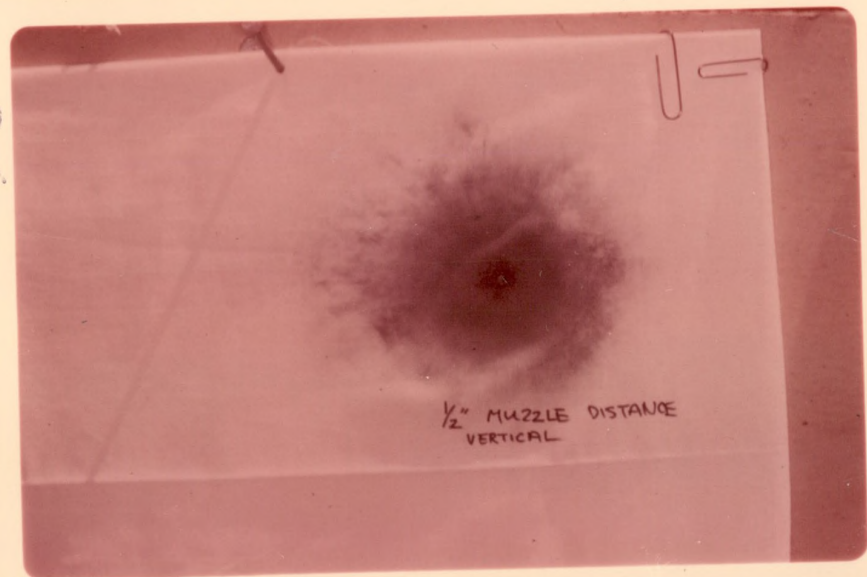
C4



C5



C6





65K



64K

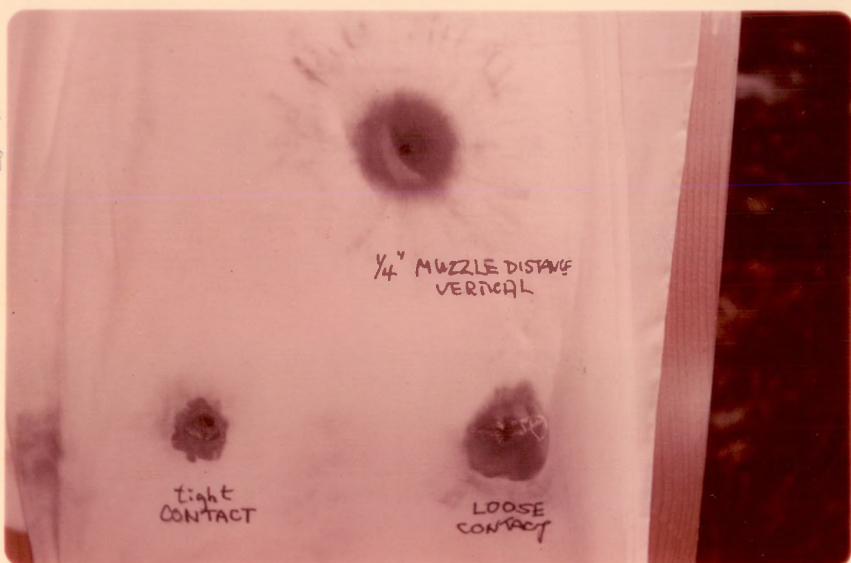


63K

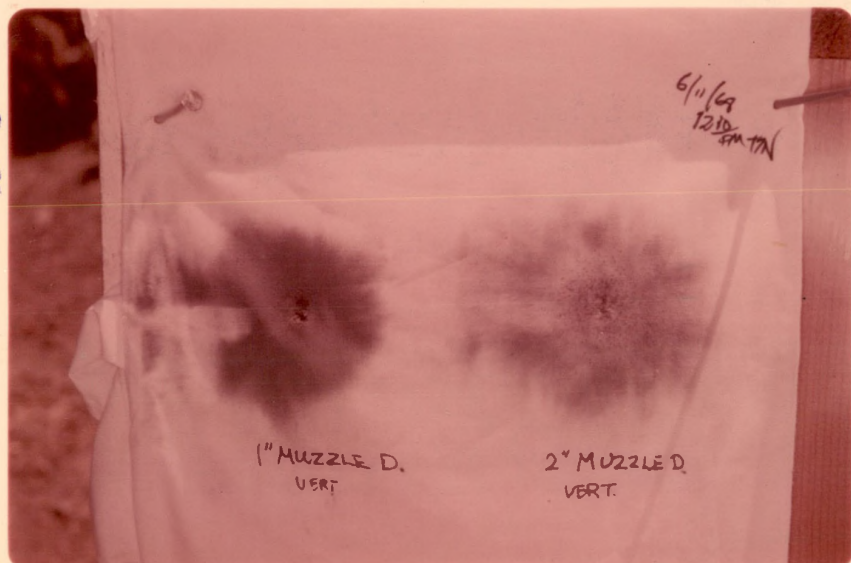




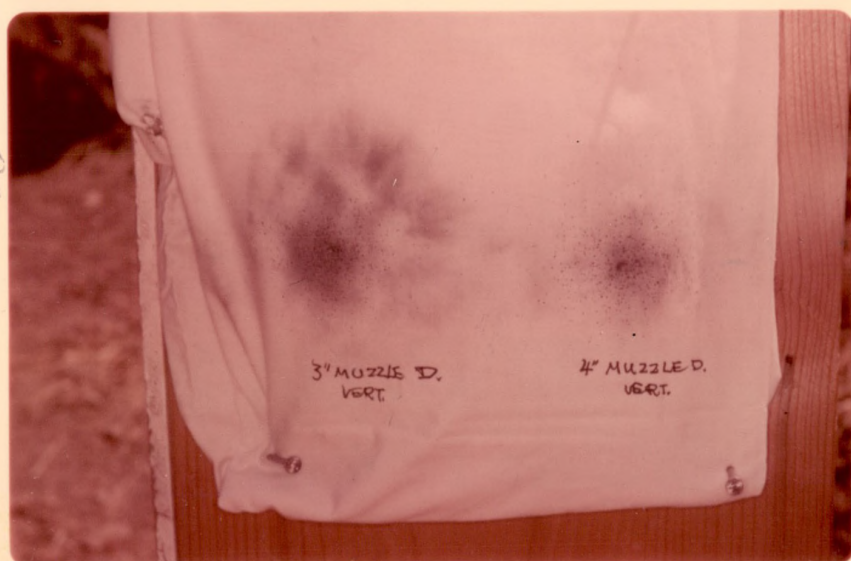C-7



C-8



C-9





68K



67K

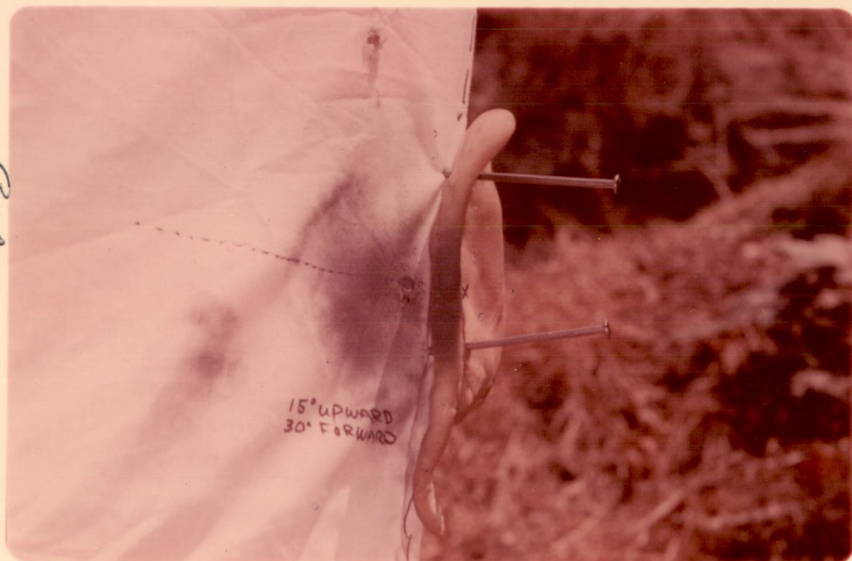

66K







C10



C11



C12







71K

70K




69K






C-13



C-14



C-15





74K


73K



72K








C18



C18



C18

76b




76K



75K



C19



C20



C21





804

166

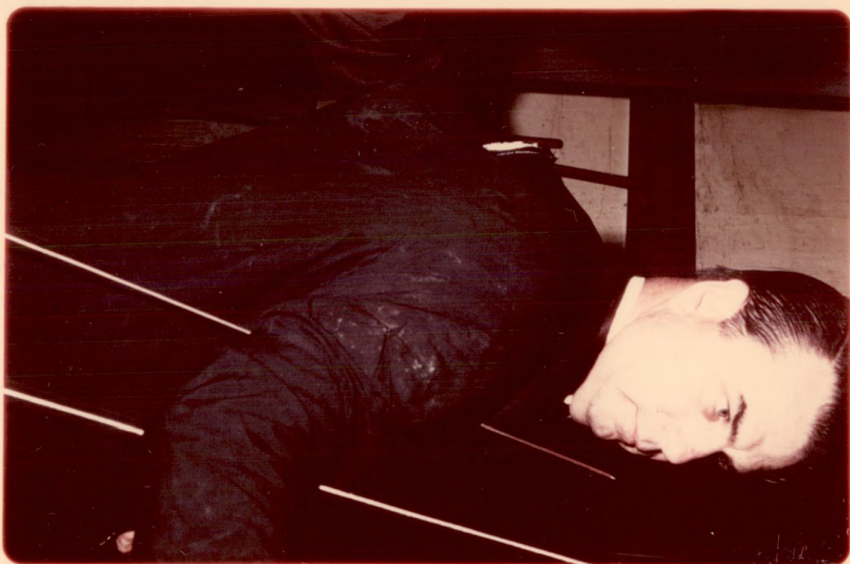


181





0-22



0-23



0-24



83K



82K



81K





C25



C26



C27



86K




85K



84K





C28



C29



C30

89K



88K



87K





C-31



C-32



~~80K~~ 91K



90K



F B I

Date: 6/6/68

Transmit the following in \_\_\_\_\_  
(Type in plaintext or code)Via AIRTEL AIR MAIL - REGISTERED  
(Priority)

Mr. Tolson	✓
Mr. DeLoach	✓
Mr. Mohr	
Mr. Bishop	
Mr. Casper	
Mr. Callahan	
Mr. Conrad	
Mr. Felt	
Mr. Gale	✓
Mr. Rosen	
Mr. Sullivan	
Mr. Tavel	
Mr. Trotter	
Tele. Room	
Miss Holmes	
Miss Gandy	

TO: DIRECTOR, FBI

ATTN: ASSISTANT TO THE  
DIRECTOR CARTHA D.  
DE LOACH

FROM: SAC, LOS ANGELES (56-156)

RE: KENSALT

Enclosed are 14 photographs made of ROBERT F. KENNEDY during the postmortem examination and coroner's autopsy.

The enclosed photographs were made by CHARLES COLLIER, Scientific Investigations Division, Photography Laboratory, Los Angeles Police Department.

The enclosed photographs are submitted for information only. Official colored photographs are being developed and will be made available.

20 JUN 8 1968

ENCLOSURE

4 - Bureau (Encls. 14) (RM)  
3 - Los Angeles

SCM/kaf  
(7)

C. C. - Bishop

Approved: \_\_\_\_\_ Sent \_\_\_\_\_ M Per \_\_\_\_\_  
Special Agent in Charge



RECEIVED-DIRECTOR  
FBI

JUN 8 3 49 PM '68

REC'D JUN 10 4 38 PM '68  
DE LOACH

JUN 8 4 18 PM '68

JUN 10 4 31 PM '68 FBI  
U.S. DEPT. OF JUSTICE

JUN 10 4 21 PM '68  
RECEIVED JUN 10 5 01 PM '68  
FBI

REC'D DE LOACH  
FBI

deleted and will be made available  
information only. On 10/10/68, the enclosed  
the enclosed information was submitted for

typewritten for the enclosed letterhead  
copying. Enclosed are two copies of the enclosed  
the enclosed information was made by the

enclosed.  
KIMBLE during the investigation and the enclosed  
enclosed the two copies of the enclosed

RE: KIMBLE  
FROM: SAC, LOS ANGELES (92-122)

TO: DIRECTOR, FBI  
FROM: SAC, LOS ANGELES (92-122)

VIGOR VIGOR - REGISTERED

Mr. Tolson	
Mr. DeLoach	
Mr. Mohr	
Mr. Bishop	
Mr. Casper	
Mr. Callahan	
Mr. Conrad	
Mr. Felt	
Mr. Gale	
Mr. Rosen	
Mr. Sullivan	
Mr. Tavel	
Mr. Trotter	
Tele. Room	
Miss Holmes	
Miss Gandy	



ROUGH DRAFT

Re-edited 9/26/68 JEH

Senator Robert F. Kennedy  
#68-5731

NOTES TO ACCOMPANYING 35 mm KODACHROME TRANSPARENCIES

TAKEN BY JOHN E. HOLLOWAY, MD. AT AUTOPSY

GENERAL NOTES:

Alpa camara, single lens reflex, with 50 mm, f/1.8 apochromat Switar lens. Honeywell ring light. Eastman Kodachrome II film. Aperture for all photographs taken at ratio 1:10 was f/8. Aperture for ratios 1:12 and 1:15 was f/5.6. Other apertures as designated. Shutter speed 1/50 sec. All photographs taken in frontal, sagittal, or vertex planes unless otherwise designated.

FRAME ONE: A-1:

Full face before removal of dressings. The ecchymosis of the right eyelid is noted (1:10).

FRAME TWO: A-2:

Left lateral view before removal of dressings (1:12).

FRAME THREE: A-3:

Right lateral view of head and shoulder region, including bandaged area of wound of exit in right medial shoulder region (1:12).

FRAME FOUR: A-4:

Anterior torso view showing tracheostomy and portion of bandage related to wound of entry in right mid-shoulder region (1:15).

FRAME FIVE: A-5:

Vertex view before removal of bandages (1:12).

FRAME SIX: A-6:

Mid-torso region showing elastoplast bandages in right femoral region and a surgical hypodermic-injection site in left inguinal femoral region (1:15).

FRAME SEVEN: A-7:

Anterior foreleg region showing cutdown with associated bandages still in place (1:15).

ROUGH DRAFT

2

#68-5731

FRAME EIGHT: A-8:

General posterior view of head and torso, from a distance of six feet. Conventional strobe-flash illumination at f/11.

FRAME NINE: A-9:

Frontal view of face and neck region following removal of head bandages but with tracheostomy tube still in place (1:10).

FRAME TEN: A-10:

Right axillary region with right upper extremity hyperextended along vertical axis to disclose wounds of entry Numbers 2 and 3. The distance between centers of these wounds of entry is about 1-1/8 inches with the degree of stretching imposed (1:10).

FRAME ELEVEN: A-11:

Medial aspect of right foot, showing cutdown region (1:10).

FRAME TWELVE: A-12:

Right femoral region, showing intactly-sutured incision (1:10).

FRAME THIRTEEN: A-13:

Right profile of head following removal of bandage, showing hemorrhage at right external auditory meatus and a portion of the surgical incisions in the right post-auricular region. Also shown is the transverse tracheostomy incision (1:10).

FRAME FOURTEEN: A-14:

Same stance as Frame Thirteen but with right ear reflected anteriorly by assistant to disclose fully the extent of the surgical incision (1:10).

FRAME FIFTEEN: A-15:

Same stance as Frames Thirteen and Fourteen. The right ear is shown partially reflected anteriorly by an assistant to demonstrate the presence of powder tattoo on the posterior aspects of the mid helix (1:10).

FRAME SIXTEEN: A-16:

Right-profile view of head after application of reference markings by Dr. Noguchi (1:10).

FRAME SEVENTEEN: A-17:

Full face view, including anterior neck region to emphasize location of tracheostomy incision (1:10).



ROUGH DRAFT

3

#68-5731

FRAME EIGHTEEN: A-18:

Right-profile view after application of reference markings by Dr. Noguchi, and taken from slightly lower aspect than Frame Sixteen. The "V" marking was applied by the undersigned to indicate, at its apex, that area designated by Doctor Cuneo at the time of autopsy as representing the wound of entry in terms of his examination before and at the time of surgery (1:10).

FRAME NINETEEN: A-19:

Right-profile view at same stance as frame number eighteen with the right ear reflected anteriorly by an assistant to show the point of wound of entry, as designated by Doctor Cuneo in relation to the surgical incision rendered visible in its entirety (1:10).

FRAME TWENTY: A-20:

Probe traversing the through-and-through gunshot wound, the leading end protruding from the wound of exit for several inches. Also visible is a thinner probe following the trajectory of the gunshot wound in the right axillary region, having no wound of exit, and from the depth of which the bullet was recovered by Dr. Noguchi. This frame includes what is interpreted as an artifact at the right margin, apparently the power cord markedly out of focus (1:13).

FRAME TWENTY-ONE: A-21:

Right axillary region as viewed anteriorly (distance about 3 feet).

FRAMES TWENTY-TWO, TWENTY-THREE AND TWENTY-FOUR: A-22,23,24:

Triangulation photographs in the frontal, vertex, and right sagittal aspect, respectively, and with the right upper extremity positioned by Dr. Noguchi in an attitude of apparent conformation with the probed gunshot-wound path.

FRAME TWENTY-FIVE: A-25:

View taken about 3 feet in distance from the right axillary region, showing the right upper extremity extended in a nearly transverse plane and anteriorly, with respect to the body axis. The optical axis of the camera is aligned with that of the probe in situ, insofar as this is possible to arrange.

ROUGH DRAFT

4

#68-5731

FRAME TWENTY-SIX: A-26:

Right axillary and right lateral thoracic region with the right upper extremity about 135 degrees clockwise from the mid-sagittal plane, viewed anteriorly and commencing in the lower left quadrant. Arbitrary delineation of the anterior, middle and posterior axillary lines has been made by Dr. Noguchi. A probe is in place in the wound of entry of the through-and-through gunshot wound (1:10).

FRAME TWENTY-SEVEN: A-27:

Preliminary dissection of the neck region such as to expose the carotid vasculature for postmortem angiography. This frame is considerably underexposed, apparently on the basis of incomplete recharging of the electronic flash condensor, in that an aperture of f/8 was used, as in all other exposures in this series involving the reproduction ratio of 1:10.

FRAME TWENTY-EIGHT: A-28:

The usual body cavities exposed by the traditional Y incision. Superfluous diaphragm has been dissected away to allow a better delineation of the level of the diaphragm. The heart has just been removed. A small amount of atelectasis appears to be present. There is a small amount of gaseous gastric dilatation, as well (1:15).

FRAME TWENTY-NINE: A-29:

Vertex of the head following reflection of the scalp, posteriorly and anteriorly, in the usual manner. Fresh hemorrhagic material is noted in the right occipital region and extending well into the right post-auricular region (1:10).

FRAME THIRTY: A-30:

Left-lateral view of the head with the same degree of dissection as accomplished in Frame Twenty-nine. A small area of hemorrhagic discoloration with irregular borders is noted in the left fronto-parietal region, as reflected forward (1:10).

FRAME THIRTY-ONE: A-31:

Right lateral view under conditons corresponding to Frames Twenty-nine and Thirty. In this view, the right post-auricular region is partially seen, along with the usual degree of post-surgical hemorrhage diffusion augmenting the traumatic hemorrhage (1:10).



ROUGH DRAFT

5

#68-5731

FRAME THIRTY-TWO: A-32:

Shows the area of the wound of entry to the head, the extent of neurosurgical bony defect, and the presence of apparent gelfoam within the augmented cavity. A centimeter scale is included in the plane of focus, the margins of the surgical defect (1:10).

FRAME THIRTY-THREE: A-33:

Same stance as Frame Thirty-two after removal of the gelfoam from the cavity, along with a certain proportion of the associated hemorrhagic material. Contused brain tissue is visible (1:10).

FRAME THIRTY-FOUR: A-34:

A so-called "open book" view of the calvarium and the cranial content before further dissection. Approximately along the midline of this frame is the point of contact of the left margin of the removed calvarial portion and its counterpart of the base of the skull (left lateral aspect). Thus, the edge of calvarium seen at the extreme left of the frame corresponds to the right lateral aspect of the base of the skull, notch for notch. It was possible to separate completely the dura from the calvarium in the process of removal of the latter. Varying degrees of subdural hemorrhage are appreciated through the translucent dura in situ, with respect to the brain (1:10).

FRAME THIRTY-FIVE: A-35:

Same general stance as Frame Thirty-four but re-oriented on the frame for emphasis. The left half of the dura has been reflected to the right, exposing the cortex of the left hemisphere, as well as its apposed subdural surface (1:10).

FRAME THIRTY-SIX: A-36:

Same stance as the preceding two frames showing the right half of the dura reflected to the left, disclosing the cortical surface of the right hemisphere and the corresponding subdural aspect (1:10).

Six additional photographs are taken on the succeeding roll of film. Serial numbering will begin with B-1.

FRAME ONE: B-1:

Anterior view of the thoracic and abdominal cavities after removal of organs and the entirety of the diaphragm. The absence of obvious direct trauma to the skeleton in the depicted area is noted. The varying degrees of hemorrhagic material seen scattered at various bilateral areas along the spine represent persistent oozing of severed intercostal vessels (1:15).

ROUGH DRAFT

6

#68-5731

FRAME TWO: B-2:

Base of the skull following removal of the brain but before the dura is disturbed. Varying amounts of subdural hemorrhage of recent origin are seen. An evident fracture of the right orbital plate is noted (1:10)

FRAME THREE: B-3:

Subsequent view of the base of the skull following removal of most of the dura. The lifting fracture of the right orbital plate is clearly seen. The region of the wound of entry is seen in part (1:10).

FRAME FOUR: B-4:

Another view of the base of the skull but taken slightly to the left of midline to demonstrate more of the area in the right mastoid region, including the surgical margin (1:10).

FRAME FIVE: B-5:

Subsequent view of the cleaned body cavity following exposure of the spinal canal and showing the spinal dura intact before the removal of the spinal cord (1:15).

FRAME SIX: B-6:

Right lateral view of the head following removal of an irregularly rhomboidal segment of bone of the skull to include the surgical margin and a portion of the wound of entry in the right mastoid region (1:10).

No further exposures are taken on this roll.

JOHN E. HOLLOWAY, M.D.  
DEPUTY MEDICAL EXAMINER

JEH:AMJ  
9/27/68



ROUGH DRAFT

1

File No. 68-5731  
Senator Robert F. Kennedy  
June 6, 1968

Edited 6/21/68  
JEH

NOTES to accompany 35 mm Kodachrome transparencies, series C, pertaining to Case 68-5731, taken by Dr. Holloway on June 11, 1968.

NOTE: The assigned frame numbers are for continuity of presentation and do not coincide necessarily with chronological frame numbers given in the usual manner by film processor.

C-1:

A composite of the pistol supplied by Sgt. Wolfer, LAPD Crime Lab, along with ammunition known to be from the identical lot as that used by the assailant. The pistol is not the actual weapon used by the assailant (that pistol being held as evidence by the court) but this test weapon is of identical manufacture, corresponding as much as possible to the fatal weapon.

C-2:

More duplicate of C-1, but both frames are somewhat overexposed due to combined sunlight and strobe flash at 1/50 second.

C-3:

Shows the test background as set up by Sgt. Wolfer and his associate. The site is the maintenance yard adjacent to the Police Academy Firing Range in Elysian Park. The test background is about 3/8 inch gypsum board with target surface of white cloth, single thickness.

C-4:

Test firing with muzzle in firm contact.

C-5:

Test firing with muzzle 1/4 inch distant from the target and the barrel axis perpendicular to the target.

C-6:

Identical geometry to that of C-5 but with a muzzle distance of 1/2 inch to target.

C-7:

Three test firings into re-arranged target. The target surface remains a single thickness of white cotton muslin but padded by several crumpled thicknesses of the same material to afford about one inch from the face of the target to the 3/4 inch wood backing. As denoted in the photograph, the firings are with

tight contact, loose contact, and with 1/4 inch distance between muzzle and target with the barrel axis perpendicular to target in all cases. Distinct radial smudge patterns are seen in the 1/4 inch distance shot, corresponding to land and groove characteristics of the barrel.

C-8:

Additional test shots with one inch and two inch muzzle distances respectively.

C-9:

Additional test shots with muzzle distances of three inches and four inches respectively. At the four-inch distance discrete tattoo particles can be made out.

C-10:

This is the first of a series of test firings at geometry simulating the fatal gunshot wound. In this series the right post-auricular scalp surface is simulated by the padded muslin as just described ✓ and the ear is simulated by a hog's ear as obtained from an abbatoir and with the hair removed. As noted on the target, the trajectory is approximately 15 degrees upward and 30 degrees forward in an approximation of the angles determined by Dr. Scanlan, Radiologist of Hospital of the Good Samaritan. His data were derived by goniometry of x-ray films and by inspection of the segment of skull removed at time of autopsy, which specimen includes a portion of the wound path through the right mastoid bone.

C-11:

Same geometry as in C-10 but with muzzle one inch from the sheet ("scalp") and 1/8 inch from the right "ear".

C-12:

Same conditions as in C-11, except for a one inch distance from the muzzle to the right "ear".

C-13:

This frame shows the suspended ceiling in the kitchen area where the Senator was shot. The missing panel in the suspended false ceiling depicted is held as evidence by others. Shown on the actual plastered ceiling above is the site of two deflected shots. The trajectories of these shots have been extensively studied by ballistics experts of LAPD. Cross reference is made to their reports and their photographs.



C-14:

Another view of the false ceiling with the adjacent panel removed to permit the placement of a probe in contact with one of the impact sites such as to allow the probe to be perpendicular to the ceiling plane.

C-15:

Similar photograph with the probe in contact with the other impact site. Near the middle of this frame at the bottom is seen the white twine used by the ballistics team of LAPD in reconstructing the trajectories.

C-16:

An approximation by Dr. Noguchi of the possible stance of Senator Kennedy at the time he sustained the first gunshot wound. The heels of the chalked-in shoe outlines are nearest the top of this frame, and the toes nearest the bottom. Dr. Noguchi has indicated by a broken line the probable direction of fall of Senator Kennedy subsequent to the gunshot wounds. The line is drawn arbitrarily from the hypothetical left heel region. Also plainly visible in this frame, for future reference, are the concrete finishing lines in the floor. The line nearest the top of this frame is parallel to the ice machine wall. The line in the floor nearest and parallel to the left margin of this frame is parallel to the end of the steam deck.

C-17:

View of the scene of the shooting. The ice machines are on the left in this view. The hypothetical location of the Senator's feet and the dotted line extending to the point where the Senator had slumped to the floor can be clearly seen. The white twine visible in the right quarter of this frame represents a trajectory line as established by the ballistics team.

C-18:

Companion view with C-17, taken at 90 degree angle, looking into the ice machine wall. The steam deck is off-scene to the left.

C-19:

Reenactment by Dr. Noguchi of possible stance of Senator Kennedy in the first postural phase upon having reached the floor.

C-20:

Reenactment of possible stance of Senator Kennedy at the time he sustained Gunshot Wound No. 2 (through-and-through). Dr. Noguchi is seen on the right, adjusting the actual coat worn by Senator Kennedy and here partially fitting to Sgt. Wolfer in conformity

with the trajectory set up by Sgt. Wolfer and his associate, as depicted in the preceding frames.

C-21:

A closer view of Dr. Noguchi in the background and Sgt. Wolfer. A probe has been placed through the holes in Senator Kennedy's coat corresponding to the Gunshot Wound No. 2. This probe is then aligned with the twine representing the bullet trajectory (and passing from low mid-left to high mid-right in this frame). This stance assumed by Sgt. Wolfer depicts another possibility of the Senator's position in terms of statements of witnesses, the knowledge that the Senator was in the process of shaking hands with culinary personnel, and other considerations tending to minimize the expected variations possible around the trajectory axis.

C-22:

Sgt. Wolfer is seen in the same stance as in frame C-21 but from the right.

C-23:

Shows Dr. Noguchi observing alignment of probe passed through the two holes in Senator Kennedy's coat, in the right superior shoulder region. These holes were not noted at the first examination of the clothing by Dr. Holloway. The holes proved to be through the coat fabric proper and a portion of the interlining of the garment, but not through the lining proper. A police officer is simulating Senator Kennedy in the stance of shaking hands but with the right shoulder elevated sufficiently to permit the "hiking up" of the right shoulder portion of the coat, which would permit trajectory through the coat but sparing the body of the Senator. Again alignment is indicated with the trajectory string.

C-24:

Depicts the unusually awkward stance which would be required for the trajectory passing through the right shoulder region of the coat alone to have been also that of Gunshot Wound No. 1 to the head. Not only would the posture have been very awkward, but the well documented trajectory of Gunshot Wound No. 1 could not, within any conceivable anatomical range of motion, also coincide. Other considerations, such as the tattoo and soot pattern of Gunshot Wound No. 1 and photographic studies of the trajectories through the cloth of the coat, also preclude the foregoing hypothesis.

C-25:

A possible alignment with the string trajectory parallel to probe passing through Gunshot Wound No. 2 (through and through).

C-26:

Same stance as in C-25. Frontal view. The right arm has been raised as in a defensive gesture following a possible previous gunshot wound. The probe passes through the entry below and the exit above of Gunshot Wound No. 2.

C-27:

Another possibility incorporating a defense gesture on the part of the Senator.

C-28:

Same stance as in C-27 with a right posterolateral view.

C-29:

First of a series of four views to simulate problems of depth of perception which may have been experienced by the female witness whose statements are a matter of record elsewhere. Arbitrary combinations of position of Senator Kennedy (simulated by the officer in shirt sleeves) and the assailant (simulated by Dr. Noguchi) are depicted. Dr. Noguchi has assigned arbitrary locations on the floor by means of dotted circles. Broken lines in chalk on the floor in the foreground represent possible paths traversed by the assailant between the ice machines on the left and the steam table on the right. In this view the victim is several feet beyond the arbitrary location and the assailant is at the arbitrary location.

C-30:

Same camera distance as in C-29. The victim still beyond the arbitrary location and the assailant nearer the camera (witness) than the arbitrary location.

C-31:

Same camera location as in C-29 and 30. The victim and the assailant are both at the arbitrary locations.

C-32:

Same camera location as in the preceding three frames. The victim is at the arbitrary location and the assailant at a point nearer the camera (witness). The stance in the four frames of this sequence is that simulating conditions compatible with, if not required by, the known geometry of fatal Gunshot Wound No. 1.

JOHN E. HOLLOWAY, M.D.  
DEPUTY MEDICAL EXAMINER

JEH:AMJ:C  
9/24/68



ROUGH DRAFT

1

Senator Robert F. Kennedy  
#68-5731

2nd rough draft,  
edited 6/21/68 - JEH

"Dr. Holloway with dictation on the first composite gross protocol  
for case 68-5731."

re-edited 7/18/68 by TTN and JEH.  
re-edited 9/20/68 by JEH.

ANATOMICAL SUMMARY

GUNSHOT WOUND NO. 1 (FATAL GUNSHOT WOUND)

ENTRY: Right mastoid region.

COURSE: Skin of right mastoid region, right mastoid, petrous  
portion of right temporal bone, right temporal lobe,  
right cerebellum, and brain stem.

EXIT: None.

DIRECTION: Right to left, slightly back to front upward.

BULLET RECOVERY: Fragments (see text).

GUNSHOT WOUND NO. 2, THROUGH-AND-THROUGH.

ENTRY: Right axillary region.

COURSE: Soft tissue of right axilla and right infraclavicular  
region.

EXIT: Right infraclavicular region.

DIRECTION: Right to left, back to front upward.

BULLET RECOVERY: None.

GUNSHOT WOUND NO. 3.

ENTRY: Right axillary region (just below Gunshot Wound No. 2  
entry).

COURSE: Soft tissue of right axilla, soft tissue of right  
upper back to the level of the 6th cervical vertebra  
just beneath the skin.

EXIT: None.

DIRECTION: Right to left, back to front, upward.

BULLET RECOVERY: .22 caliber bullet from the soft tissue of paracervical region at level of 6th cervical vertebra at 8:40 A.M. June 6, 1968.

GUNSHOT WOUND NO. 1:

The wound of entry, as designated by Maxwell M. Andler, Jr, M.D., Neurosurgeon attending the autopsy, and more or less evident by inspection of the apposed craniotomy incision, is centered 5 inches (12.7 cm) from the vertex, about 3/4 inch (1.9 cm) posterior to the center of the right external auditory meatus, about 3/4 inch (1.9 cm) superior to the Reid line, and 2-1/2 inches (6.4 cm) anterior to a coronal plane passing through the occipital protuberance at its scalp-covered aspect. The defect appears to have been about 3/16 inch (0.5 cm) in diameter at the skin surface. The surgical incision passing through the area of the wound of entry has been fashioned in a semilunar configuration with the concavity directed inferiorly and posteriorly. The incision has been intactly sutured by metallic and other material. The arc length is about 4 inches (10 cm).

Further detailed description of the area is given in the Neuro-pathology portion of this report.

Varyingly moderate degrees of very recent hemorrhage are noted in the soft tissue inferior to the right mastoid region, extending medially, as well. There is no hematoma in the soft tissue.

In conjunction with the wound of entry, the right external ear shows, on the posterior aspect of the helix, an irregularly fusiform zone of dark red and gray stippling about one inch (2.5 cm) in greatest dimension, along the posterior cartilaginous border and over a maximum width of about 1/4 inch (0.6 cm) at the midportion of the stippled zone. This widest zone of stippling is approximately along a radius originating from the wound of entry in the right mastoid region. Moderate edema and variable ecchymosis is present in the associated portions of right external ear as well.

GUNSHOT WOUND NO. 2:

This is a through-and-through wound of the right axillary, medial shoulder, and anterior superior chest areas, excluding the thorax proper. The wound of entry is centered 12-1/2 inches (13.6 cm) from the vertex, 9 inches (22.9 cm) to the right of midline, and

3-3/4 inches (8.3 cm) from the back (anterior to a coronal plane passing through the surface of the skin at the scapula region). There is a regularly elliptical defect 3/16 x 1/8 inch over-all (about 0.5 x 0.3 cm) with thin rim of abrasion. There is no apparent charring or powder residue in the adjacent and subjacent tissue. The subcutaneous fatty tissue is hemorrhagic.

The wound path is through soft tissue, medially to the left, superiorly and somewhat anteriorly. Bony structures, major blood vessels and the brachial plexus have been spared.

The exit wound is centered 9-3/4 inches (about 24.5 cm) from the vertex and about 5 inches (about 12.5 cm) to the right of midline anteriorly in the infraclavicular region. There is a nearly circular defect slightly less than 1/4 inch x 3/16 inch overall (0.6 x 0.5 cm).

Orientation of the wounds of entry and exit is such that their major axes at the skin surfaces coincide with the central axis of a probe passed along the entirety of the wound path. No evidence of deflection of trajectory is found.

#### GUNSHOT WOUND NO. 3:

The wound of entry is centered 14 inches (35.6 cm) from the vertex and 8-1/2 inches (21.6 cm) to the right of midline, 2 inches (5 cm) from the back anterior to a plane passing through the skin surface overlying the scapula, and 1/2 inch (1.2 cm) posterior to the mid-axillary line. There is a nearly circular defect 3/16 inch by slightly more than 1/8 inch overall (0.5 x 0.4 cm). There is a thin marginal abrasion rim without evidence of charring or apparent residue in the adjacent skin or subjacent soft tissue. The subcutaneous fatty tissue is hemorrhagic.

The wound path is directed medially to the left, superiorly and posteriorly through soft tissue of the medial portion of the axilla and soft tissue of the upper back, terminating at a point at the level of the 6th thoracic vertebra as close as about 1/2 inch (1.2 cm) to the right of midline.

**Bullet Recovery:** A bullet of .22 caliber with lubaloy covering is recovered at the terminus of the wound path just described, at 8:40 A.M. June 6, 1968. There is a unilateral, transverse deformation, the contour of which is indicated on an accompanying diagram. The initials, TN, and the numbers 31 are placed on the base of the bullet for future identification. The usual Evidence envelope is prepared. The bullet, so marked and so enclosed as evidence, is given to Sergeant W. Jordan, No. 7167, Rampart Detectives, Los Angeles Police Department, at 8:49 A.M. this date for further studies.



An irregularly bordered and somewhat elliptical zone of variably mottled recent ecchymosis is present in the superior-medial axillary skin on the right, in the zones of wounds of entry No. 2 and No. 3, especially the former. The ecchymosis measures 3-1/2 x 1-1/2 inches (9 x 3.8 cm) overall with the right upper extremity extended completely upward(longitudinally).

#### EXAMINATION OF CLOTHING AT TIME OF AUTOPSY:

1) There is a dark blue, fine worsted-type suit coat bearing the label "Georgetown University Shop - Georgetown, D.C". The coat has been cut and/or torn at the left yoke and left sleeve area. The right sleeve is intact. There is variable blood staining over the right shoulder region and on the right lapel. Two apparent bullet holes are identified in the right axillary region, slightly over 1 inch (2.5 cm) and slightly over 1-1/4 inch (3.2 cm) from the underseam area, respectively, and corresponding with wounds described on the body elsewhere in this report. Also noted at the top of the right shoulder region, centered about 1-1/4 inches from the shoulder seam and about 5/8 inch (1.6 cm) posterior to the yoke seam superiorly is an irregular rent of the fabric, somewhat less than 1/4 inch (3.2 cm) in diameter and definitely evertting superficially and upward. The 3 front buttons of the garment are intact.

Subsequent examination of the coat showed the presence of a superficial through-and-through bullet path through the upper right shoulder area, passing through the suit fabric proper, but not the lining.

2) There is a pair of trousers of matching material with a very dark brown leather belt with rectangular metal buckle and showing the gold-stamped label "Custom Leather, Reversible, 32". The zipper is intact. There is a minimal amount of apparent blood staining over the anterior portions of the trouser legs.

3) There is a white cotton shirt with the label "K WRAGGE, 48 West 46th Street, New York". The laundry mark initials "RFK" are present on the neck band. The left portion of the shirt has been disrupted in approximately the same manner as the suit coat and is similarly absent. The right cuff is intact and is of semi-French design. A chain-connected yellow metal cufflink with plain oval design is in place. A corresponding left cufflink is not among the items submitted. Apparent bullet holes are identified as corresponding to those in the previously described area of suit coat.

4) There is a tie of apparent silk rep, navy blue with an approximately 3/16 inch (0.5 cm) grey diagonal stripe. The label is "Chase and Collier, McLean, Virginia". The maker is RIVETZ.

- 5) There is a pair of navy blue, nearly calf length socks of mixed cashmere and apparently nylon fiber, the fiber content stencil labeling still being nearly discernible on the foot portions.
- 6) There is a pair of white broadcloth boxer type shorts with two labels: "Sunsheen Broadcloth V'Cloth - 34; and "Custom fashioned for Lewis and Thos. Saltz, Washington". There is a small amount of blood stain at the anterior crotch, along with pale straw colored discoloration to the left of the fly. A few patches of dry blood are present on the back as well.
- 7) There is a trapezoidally folded cotton handkerchief showing, on what appears to be the presenting (anterior) surface, several scattered dark red and somewhat brown spots ranging from a fraction of a millimeter to about 4 mm (less than 3/16 inch) in greatest dimension.
- 8) No shoes are submitted for examination.

The above listed items are saved for further and more detailed study by others.

#### GENERAL EXTERNAL EXAMINATION:

The non-embalmed body, measuring 70-1/2 inches (179 cm) in length and weighing about 165 pounds (74.5 kg), is that of a well-developed, well-nourished and muscular Caucasian male appearing about the recorded age of 42 years. The extremities are generally symmetrical bilaterally, showing no obvious structural abnormality.

The head shows extensive bandaging, somewhat blood-stained in the posterior aspect. Dressings are also present in the right clavicular region, the right axilla, and the right ankle regions. Also present over the right inguino-femoral region are apparently elastoplast dressings. A recent tracheostomy has been performed at a comparatively low level. A clear plastic tracheostomy tube fitted with an inflatable cuff is in place. The area also shows a gauze dressing.

Lividity is well developed in the posterior aspect of the body, mainly at the upper shoulder and midback regions with approximately equal distribution bilaterally. The lividity blanches definitely on finger pressure.

Rigor mortis is not detected in the extremities or in the neck.

Rigor was noted to be developing in the arms and legs by the time of conclusion of the autopsy.

A complete examination of the external surfaces of the body is undertaken following removal of all dressings.

The head contour is generally symmetrical, due allowance being made for the soft-tissue edema and hemorrhage in the right post-auricular region in general. The hair is graying light brown and of male distribution. Calvity lines are well delineated on the scalp. Portions of the right half of the scalp have clipped and/or shaved. Hair in the inguinal and femoral regions has also been shaved in part. Hair texture is medium.

There is an irregularly bordered area of comparatively recent yet pale ecchymosis centered about one inch (2.5 cm) above the midportion of the right eyebrow. Marked ecchymosis with moderate edema is present in the right periorbital region but mainly of the upper eyelid. No abnormality is noted in the left periorbital tissue externally. No hemorrhage or generalized congestion is seen in the conjunctival or scleral membranes. The nose is symmetrical, showing no evidence of fracture or hemorrhage. The glabella shows no evidence of trauma.

Eye color is hazel. Pupillary diameters are equal at about 5 mm (3/16 in).

The buccal mucosa and the tongue show no lesion.

Chest diameters are within normal limits and there is bilateral symmetry. The breasts are those of a normal adult male. The abdomen is scaphoid. No abdominal scar is identified. There is an old low medial inguinal scar on the right.

Texture and configuration of the nails are within normal limits, and no focal lesions are noted. There is no peripheral edema.

The skin in general shows a smooth texture and no additional significant focal lesion. There is abundant sun tan, especially at the neck region where its contrast with the areas shaved for surgical preparation on the right can be noted. No evidence of powder burn, tattoo, or stippling is found in the area surrounding the wound of entry of Gunshot Wound No. 1, in an arbitrary circular zone to include the above-described stippling on the right ear, or beyond.

No structural abnormality is noted on the back.

There is a diagonally disposed recent surgical incision about 3 inches (7.5 cm) in length in the right anterolateral femoral region. This incision has been intactly sutured. There is an associated plastic tubing of small diameter, centered about 1/2 inch (12 mm) from the infero-medial margin of the incision.



Also noted in a comparable location on the left are several hypodermic puncture marks. These just-mentioned areas show the presence of red-orange dye.

There are recent cutdowns at the right ankle and the lateral right knee with thin polyethylene tubes in place. No extravasation is noted.

The external genitalia are those of a normal circumcised adult male.

#### CAVITIES:

Primary incision is first made as far as the two upper incisions, allowing upward reflection of skin and soft tissue to afford access for carotid angiography before the head is opened. Following completion of these roentgenographic studies, the traditional Y incision is continued. The peritoneal surfaces are smooth and glistening. No free fluid is found in the abdominal cavity. There are no adhesions. Abdominal organs are in their usual relative positions.

The pleural surfaces are smooth. There is no pleural effusion.

The pericardium is intact and encloses a small amount of transparent straw-colored liquid.

#### CARDIOVASCULAR SYSTEM:

The heart weighs 360 gm and presents smooth epicardial surfaces. There is moderate right atrial dilatation. The contour otherwise is within normal limits. Cut surfaces of myocardium show a uniform gray-red muscle fiber texture with no focal lesion. The endocardial surfaces are smooth. About 50 ml of dark red postmortem clot is present in the chambers collectively. No cardiac anomaly is demonstrated. The thickness of the left ventricular wall is up to 1.3 cm, and that of the right 0.3 cm. Valve circumferences are: Tricuspid - 13, pulmonic - 8.5, mitral - 10.5, and aortic - 7 cm. There are no focal lesions. The coronary arterial tree arises in the usual sites and distributes normally. The coronary arteries are thin-walled and pliable, showing widely patent lumina. The aorta has a normal configuration and varies from 3.3 to 5.2 cm in circumference. The intimal surface of the aorta shows small and comparatively pale yellow atheromatous areas totaling no more than 10% of the area studied.

The lining of the inferior vena cava is smooth throughout. The distal end of the intravenous polyethylene catheter is noted at the level of the 2nd lumbar vertebra and shows no evidence of thrombosis at the tip. Free flow is also demonstrated.

Other vessels studied are not remarkable, save where special descriptions are given elsewhere in this report.

#### RESPIRATORY SYSTEM:

The right lung weighs 490 gm; the left, 330 gm. There is a moderate amount of wrinkling of the external surfaces, suggestive of atelectasis. Dusky discoloration is noted in the hypostatic portions bilaterally. The outer surfaces of the lungs are intrinsically smooth. Cut surfaces of the lungs disclose a few scattered areas of atelectasis, especially in the left lower lobe. There is mild edema throughout. Hypostatic congestion is noted in an estimated 30% of the total lung volume, approximately equally distributed bilaterally. In these hypostatic areas there is probably patchy hemorrhage of the matrix as well. No areas of consolidation are identified. Non-congested portions of the lungs are comparatively pale tan in color. Anthracotic pigmentation is not excessive for the age of the subject.

A small amount of slightly pink frothy mucoid material is present in the bronchial tree, but no exudate. There is no evidence of aspiration of gastric content.

The hilar lymph nodes show no abnormality.

#### NECK ORGANS:

The pharyngeal and laryngeal mucosa shows no focal lesion. There are a few petechial hemorrhages of the epiglottis. Intrinsic musculature and soft tissue of the larynx shows no hemorrhage or other evidence of trauma. The vocal cords do not appear edematous, nor is there evidence of generalized submucosal edema. The hyoid bone is intact.

The trachea is in midline. The plastic tracheostomy tube previously mentioned shows no obstruction of its airway and no exudates or hemorrhagic material. The mucosa lining the trachea is moderately injected at the general level of the tracheostomy, again with no obvious exudate.

The thymus shows the usual atrophy and is comparatively fatty but not otherwise remarkable.

#### HEPATOBIILIARY SYSTEM:

The liver weighs 1810 gm and has a smooth intact capsule. The edges are sharp. Cut surfaces of the liver show no focal lesion

in the comparatively dark brown matrix. Little blood wells up from freshly cut surfaces. A number of normal sized portal veins present themselves. There is no evidence of fibrosis. No fatty sheen is seen on the cut surfaces.

The gallbladder has a wall of average thickness and a smooth serosal surface. The organ is distended by the presence of more than 25 ml of green-black bile of intermediate viscosity. There are no calculi. The extrahepatic biliary system is patent.

#### HEMIC AND LYMPHATIC SYSTEM:

The 150 gm spleen is moderately firm and has a smooth intact capsule. Multiple cut surfaces of the spleen show no focal lesion in the dark gray-red matrix. The capsule shows no areas of thickening. The malpighian bodies are distinct. No accessory spleen is identified.

There is no evidence of marked departure from normal blood volume. In areas where postmortem clot is found, this is of uniformly normal degree and texture. No evidence of any hemorrhagic diathesis is noted.

The abdominal lymph nodes, mainly the para-aortic, show moderate enlargement (up to three times the normal size) but no induration or focal change. Other lymph nodes studied are not remarkable.

#### PANCREAS:

Configuration and size are within normal limits. Multiple cut surfaces show no evidence of an acute inflammatory change, fatty necrosis, scarring, or hemorrhage.

#### UROGENITAL SYSTEM:

The right kidney weighs 180 gm and has a smooth capsule which strips readily. Cut surfaces disclose normal corticomedullary ratios, with an average cortical thickness of about 6 mm, compared with 1.0 cm of the medulla. There are no focal lesions. A moderate amount of engorgement is noted.

The left kidney weighs 175 gm and has a generally smooth capsule which can be stripped readily. Also present, however, is a retention cyst about 2.5 cm in greatest dimension but showing, on subsequent study, a principal volume delineated by a space 2.0 x 1.8 x 1.5 cm. Thin watery liquid is enclosed. About 3.0 cm from one pole of the left kidney and 2.0 cm from the pelvis,



is a well-circumscribed and slightly raised subcapsular nodule having a uniform yellow matrix and measuring 1.0 x 0.9 x 0.9 cm overall. The cut surface of this yellow nodule protrudes slightly. The lesion is about 6.0 cm from the just-described retention cyst. Intervening matrix of the left kidney shows no focal change. The renal pelves of both kidneys and both ureters show no induration, dilatation, or exudates. Ureteral implantation is noted to be normal in the urinary bladder. About 8 ml of faintly amber-pink cloudy urine is contained. There is no focal lesion of the urothelial lining. There are no urinary calculi.

The prostate is symmetrical with a transverse diameter of 3.5 cm. Cut surfaces show no distinct nodular areas and no focal lesion. there are scattered areas of vascular engorgement near the origin of the prostatic urethra. A slightly gritty texture is found on the cut surfaces of the prostate. Scattered discrete calculi up to 2 mm in diameter are found.

The seminal vesicles are of normal configuration and contain a small amount of green-gray mucoid material.

Both testes are present in the scrotal sac and are of normal size and consistence. Tubular stringing is readily accomplished. No evidence of hydrocele is present.

#### DIGESTIVE SYSTEM:

The esophagus is lined by smooth pale-gray epithelium following the usual longitudinal folds. No focal lesion is found. The stomach has a wall of average thickness and a smooth serosal surface. There is mild gaseous dilatation. No evidence of hemorrhage or ulceration is found in the gastric mucosa. Within the lumen is about 500 ml of cloudy gray watery mucoid material in which no discrete food fragments are found. A small amount of hemorrhagic material is inadvertently admitted into the gastric content as the latter is secured for possible toxicological studies. The duodenum, small intestine, and colon show no gross abnormalities of mucosal or serosal elements. The mesenteric lymph nodes are not remarkable.

#### ENDOCRINE ORGANS:

The pituitary is intrinsically symmetrical and within the normal limits of size, as is the sella turcica.

The thyroid is symmetrical and not enlarged; cut surfaces of the brown-red colloid matrix shows no focal change.

The adrenals total 13.5 gm and are of normal configuration. Multiple cut surfaces show no focal lesion. The thickness of the cortex is little more than one millimeter. The medullary tissue is not remarkable.

#### MUSCULOSKELETAL SYSTEM:

The bony framework is well developed and well retained. No evidence of a diffuse osseous lesion is found. The fracture of the right orbital plate and of other components of the base of the skull are described in detail elsewhere in this report, mainly the Neuropathology section. No additional evidence of recent fracture or other focal trauma is demonstrated in the skeleton.

The clinically described and radiologically documented old fractures are not dissected.

The vertebral marrow is a uniform brown-red, showing no focal change.

Cut surfaces of muscles studied, in areas apart from the trauma, show no abnormality.

#### HEAD AND NERVOUS SYSTEM:

Additional features revealed by reflection of the scalp include a fairly well demarcated area of non-recent hemorrhagic discoloration, about 1.5 cm in greatest dimension, in the left parietal-occipital region. No associated galeal hemorrhage is demonstrated.

A complete description of the brain in situ and following removal, before and after fixation, will be found elsewhere in this report.

The cerebrospinal fluid is blood tinged.

Abundant and freshly clotted but drying blood is found at the right external auditory canal, extending outward to the lateral interstices of the external ear. No evidence of hemorrhage is found at the left ear.

The spinal cord is taken for further evaluation by the Neuropathologist. At time of removal of the cord, a small amount of cervical epidural hemorrhage is noted. There is no evidence, on preliminary inspection, of avulsion of roots leading to the right brachial plexus.

ROUGH DRAFT

12

#68-5731

SENATOR ROBERT F. KENNEDY

JUNE 6, 1968

Those portions of peripheral nervous system exposed by the extent of dissection indicated above in general show no abnormality.

SPECIMENS SUBMITTED:

Organs and body fluids enumerated elsewhere in this report, for the purpose of toxicological examinations.

Tissue sections for microscopic examination as denoted in other portions of this report.

Other specimens for special studies as described in accompanying reports.

COMPLETION OF AUTOPSY:

The above-described dissections, postmortem radiographic studies, the autopsy photographs, and the placing of retained specimens in suitably labeled containers, were all completed by 9:15 A.M., this date. The body was then released to the embalmers who had arrived to perform their functions.

THOMAS T. NOGUCHI, M.D.  
CHIEF MEDICAL EXAMINER-CORONER

JOHN E. HOLLOWAY, M.D.  
DEPUTY MEDICAL EXAMINER

ABRAHAM T. LU, M.D.  
DEPUTY MEDICAL EXAMINER

JEH::AMJ::C  
9/25/68



ROUGH DRAFT

#68-5731  
ROBERT F. KENNEDY

NEUROPATHOLOGY REPORT

Abraham T. Lu, M.D.

CONTENTS

I. ABSTRACT OF PATHOLOGIC FINDINGS.....	2
II. CHRONOLOGY AND PLACES OF EXAMINATIONS, OTHER PERTINENT DATA	3
III. GROSS PATHOLOGIC FINDINGS.....	4
A. Scalp and Cranium.....	4
B. Meninges, Blood Vessels and Cranial Nerves.....	5
C. Cerebrum.....	6-7
D. Cerebellum.....	7-8
E. Brain Stem.....	8-9
F. Ventricular System.....	9
G. Spinal Canal and Spinal Cord.....	9
H. Pituitary Gland.....	9
IV. MICROSCOPIC FINDINGS.....	10
V. CORRELATIVE PATHO-ANATOMIC DESCRIPTION AND INTERPRETATION OF LESIONS.....	11
VI. SUMMARY OF ANATOMIC PATHOLOGY.....	12
A. Primary Lesions - Gunshot Wounds.....	12
B. Immediate Secondary Lesions.....	12
C. Surgical Procedures.....	12
D. Late Secondary Lesions.....	13
VII. FINAL DIAGNOSIS.....	14

## I ABSTRACT OF PATHOLOGIC FINDINGS

The wounds of the skull and the brain indicate that a bullet entered the mastoid process of the right temporal bone behind the right ear. The petrous ridge at the attachment of the tentorium shows a triangular defect about 8 mm wide at the base where the right superior petrosal sinus is torn. The bullet fragmented and several fragments of bullet and bone were driven into the brain.

The largest metallic fragment (according to pre-operative x-ray) entered the inferior surface of the right temporal lobe and produced contusion, laceration and hemorrhage of the cortex and subcortical white matter, especially of the fusiform gyrus. The wound is about 15 degrees anterior to the entrance wound in the bone.

Fragments of the bullet and bone deviated 45 degrees posteriorly and medially and 30 degrees superiorly into the right cerebellar hemisphere. A fragment of the bullet was recovered in the vermis.

The tract in the cerebellum was 5 cm long and probing indicated that it was up to 2 cm in diameter originally, although the tract was collapsed at autopsy.

Subdural and subarachnoid hemorrhage were present.

Additional contusions, hemorrhages and fractures were caused by the expansile and translational forces produced when the bullet entered the brain.

The cerebrum, cerebellum and brain stem were markedly swollen and showed secondary effects of compression and herniation including extensive hemorrhages of the midbrain and pons.

Death was caused by a combination of the immediate and delayed effects of gunshot wound of the right side of the brain.

## II CHRONOLOGY, PLACES OF EXAMINATION, OTHER PERTINENT DATA

Inspection of the head and removal of the brain, spinal cord and temporo-occipital bone began at 7:40 a.m. and was completed at 10:00 a.m., June 6, 1968 in the autopsy room of Good Samaritan Hospital, Los Angeles, California.

Preliminary examination of the brain and cranial wound was made, including two horizontal sections through the midbrain and upper portion of the pons.

Drs. James Poppen, Henry Cuneo and Nat Downs Reid were present and the brain specimen was shown to them.

The specimens were then placed in 10% neutral formalin for fixation and transferred to the LOS Angeles County Chief Medical Examiner-Coroner's office.

At 4:00 p.m., June 6, 1968, after six hours of preliminary fixation, the brain was cut in six coronal sections and examined. Records were made of all gross findings.

7:00 p.m., June 7, 1968, the brain was further cut into 13 coronal sections and re-examined. All lesions and their locations were reconfirmed and descriptions check for accuracy.

Color photographs and radiographs, including internal carotid artery angiography were made at different stages of examination.



## III GROSS PATHOLOGIC FINDINGS

## A. Scalp and Cranium

A U-shaped recent surgical wound is present over the right temporo-occipital region of the recently shaved scalp behind the right ear. Many wire sutures are in place. About 2 cm above the tip of the mastoid process immediately behind the pinna at about the level of the external auditory meatus the anterior portion of the skin of the incision shows a semi-circular defect said to be a portion of the original bullet entrance wound (according to the surgeons who were present at the examination). After removing the wire sutures the scalp is incised by the usual mastoid-to-mastoid incision across the vertex. The incision on the right is extended into the surgical incision mentioned above. After reflecting the scalp, dark red subcutaneous and subgaleal hemorrhages are found in the right temporo-occipital region overlying and around the wound and the surgical craniotomy over an area measuring 9.5 x 10 cm. The hemorrhage ranges up to 3 mm in thickness. The right temporal muscle shows a small amount of hemorrhage along its posterior aspect.

The bony defect of the cranium included the superior portions of the right mastoid process and the adjacent temporo-occipital bones in an irregularly oval area measuring 6 x 5 cm. Gelfoam and hemorrhagic material is removed from the craniotomy site.

A circumferential cut with three notches is made in the calvarium with a vibratory saw. The calvarium is removed from the underlying dura. There is no lesion in this portion of the cranium.

The bone surrounding the craniotomy is removed in a single piece, including the posterior half of the right external auditory canal. The bullet wound in the skull appears to be located with its anterior margin 1 cm posterior to the right external auditory meatus 2 cm superior to the tip of the mastoid process; but the original configuration is obscured by the surgical enlargement and by the adjacent craniotomy. The surgical opening of the right temporo-occipital bone measures 6 cm anteroposteriorly and 5 cm supero-inferiorly. Burr holes, saw cuts, and rongeur cuts can be seen along the margins of the bone.

The bullet wound of the mastoid extends medially to the base of the petrous portion where there is a triangular defect with the base of the triangle corresponding to the petrous ridge and measuring 8 mm in width.

A curved fracture about 1 cm long is found in the central thinnest portion of the right supra-orbital plate with intra-orbital hemorrhage beneath it surrounding the right eye. A laceration of the dura and contusion of the right orbital gyri are located above the fracture.

## B) Meninges, blood vessels and Cranial Nerves

In the dorsolateral aspect of the subdural space there is a film of blood up to 3 mm thick, covering the arachnoid over both posterior frontal and parieto-occipital regions and extending downward to, and in some places below the sylvian fissure bilaterally, slightly more on the left side than on the right. Similar blood clot is also found in the left middle fossa and in both posterior fossae, again more on the left side. A small amount of blood clot, about 2 cc, is found between the cerebral hemispheres just dorsal to the midbrain.

Rather diffuse subarachnoid hemorrhage is present over the parieto-occipital regions, over the dorsal and right side of the cerebellum and also over the ventral surface of the pons and medulla. All of this, however, is quite slight and the blood clot does not obscure the underlying structures.

Epidural hemorrhages are found in the following three locations:

1) Adjacent to the craniotomy defect of the right temporo-occipital region. This is minimal and extends not more than 1 cm from the surgical incision and it is less than 1 mm in thickness. (2) Above the right supraorbital plate where the fracture is present as described above. This is deemed minimal and less than 1 mm in thickness covering an area 1.5 x 1 cm. (3) Epidural hemorrhage measuring 2 cm longitudinally and 1 cm transversely is found in the dorsal aspect of the epidural space at C1 and C2 vertebral levels.

The dorsal veins which empty into the superior sagittal sinus are inspected but they reveal no evidence of the source of subdural hemorrhage.

The right superior petrosal sinus is severed for a distance of 8 mm corresponding to the defect of the petrous ridge mentioned above. The remainder of this sinus adjacent to the defect has been cauterized. The tentorium which has its attachment to the right petrous ridge is lacerated where the bony defect is present. This laceration of the dura is continued laterally and communicates with the surgical defect which measures 4.5 x 2.0 cm just anterior to the right sigmoid sinus and above the transverse sinus beneath the craniotomy opening. A second surgical defect is present on the dura posterior to the sigmoid sinus and inferior to the transverse sinus and this measures 3 x 2 cm. There are areas of brownish discoloration and a minimal amount of blood clot is scattered along the margins of these dural openings.

The lateral portion of the transverse sinus and the sigmoid sinus thus traverse the craniotomy defect horizontally through its posterior portion and vertically through its inferior portion.

The tentorium cerebelli shows no defects in its central portions.

The dura was lacerated over a small area over the right supra-orbital plate where a curved fracture was present as mentioned above.

The superior sagittal sinus, left transverse sinus, left sigmoid sinus and cavernous sinuses are inspected and reveal no evidence of thrombosis or laceration. The right transverse and sigmoid sinuses do not appear to be damaged inspite of their proximity to the dural openings anterior and posterior to it, but cautery marks are on and close to these sinuses which contain dark red blood clot.

Examination of the arteries of the brain stem and cerebellum reveals a right vertebral artery that is smaller than the left. The basilar artery measures 3 mm in diameter and is slightly tortuous. The anterior inferior cerebellar arteries and the posterior inferior cerebellar arteries have a normal distribution and show no evidence of traumatic injury. The left superior cerebellar artery is intact. The right superior cerebellar artery is intact throughout its main trunk but several of its superficial branches are involved in the cortical contusion and laceration of the cerebellum and many of its deeper branches have been damaged by the penetrating bullet and bone fragments.

All of the remaining blood vessels of the brain stem, cerebellum and cerebral hemispheres have normal distribution and show very slight atherosclerosis. There is no evidence of injury except for the areas of contusions and lacerations.

The cranial nerves are all intact.

#### C. Cerebrum

Slight depression of the cerebral cortex is noted over both posterior frontal and parietal convexities in areas beneath the subdural hemorrhage that is described above. The right cerebral hemisphere is slightly larger than the left with shallow tentorium grooves over both unci, slightly more prominent on the right than on the left. However, there is no evidence of herniation of the cingulate gyri beneath the falx. The gyri over both cerebral convexities are flattened.

When the brain is inspected from the ventral aspect, three areas of contusion-laceration can be seen in the cortex of the right cerebral hemisphere and a fourth area of contusion on the left. The largest one measures 4 x 3 cm. It consists of superficial and deep lacerations and contusions of the mesial half of the posterior one-third of the right inferior temporal gyrus for an anteroposterior distance of 4 cm; the middle third of the right fusiform gyrus for 3 cm and the lateral portion of the



hippocampal gyrus for a distance of about 1 cm. Coronal sections show that this laceration has a subcortical hemorrhage extending 1.5 cm into the subcortical white matter to the floor of the posterior part of the temporal horn of the right lateral ventricle with rupture into this cavity. The medial portions of the temporal lesion are characteristic of laceration and contusion while the lateral portions of this lesion are quite characteristic of hemorrhagic infarction.

The second largest contusion is in the middle part of the right orbital gyri and measures 1.5 x 1.0 cm with a 5 mm curved laceration within it. Hemorrhage extends into the subdural white matter to a depth of 6 mm. This lesion overlies the lacerated dura and fracture of the right supraorbital plate.

The third contusion measures 14 x 7 mm with a linear 6 mm transverse laceration and is situated in the mesial portion of the inferior part of the right occipital cortex.

The fourth contusion of the cortex is a very small lesion in the middle of the left inferior temporal gyrus and measures 5 x 2 mm. There is no laceration in this area. This contusion is limited to the gray matter.

#### D. Cerebellum

In the anterior and lateral aspects of the right hemisphere of the cerebellum there is an irregular penetrating wound. The opening measures 2 x 2 cm with irregular margins. The margins of this wound and adjacent areas are elevated to form a ring of tissue at the bony margin, 2 mm distal to the internal bone surface. This indicates herniation of the cerebellar tissue into the bony defect. On the surface of this defect and in the bone incision there are fragments of gelfoam and soft friable blood clot.

A partially collapsed linear tract measuring 5 cm in length extends from the cerebellar cortex and subcortical white matter of the cerebellum to the vermis. The tract begins just rostral to the tegmentum of the anterior one-third of the pons, anterior to the middle cerebellar peduncle and proceeds in a superior and posterior direction. From an imaginary transverse plane between the two mastoid bones, one would estimate that this tract proceeds about 45 degrees posteriorly and medially and 30 degrees superiorly from the mastoid perforation. The tract ends in the vermis of the cerebellum where a 1 cm transverse laceration is found in the region of the primary fissure which is approximately 3 cm posterior to the anterior cerebellar notch. At the termination of the tract, hemorrhage can be seen within the cortical laceration.

The size of the penetrating wound is difficult to determine at this time since the tract is largely filled by the swollen white matter of the cerebellum and by hemorrhage. However, probing into the tract at the entrance wound indicates that it was in the order of 2 cm in width at maximum expansion.

Upon palpation and probing in the region of the laceration in the superior vermis, a metallic fragment is found just beneath the arachnoid membrane and within an area of hemorrhage. This irregular gray metallic fragment measures 6 x 3 x 2 mm and corresponds to the largest fragment that was identified in the postoperative x-ray of a radiopaque object near the midline.

In addition to the penetrating wound and the laceration of the vermis at its terminal end, an area of contusion and hemorrhagic necrosis measuring 2.5 x 2.0 cm covers most of the superior surface of the right cerebellar hemisphere and extends 5 mm over the midline. Beneath this area of contusion and communicating with the penetrating wound, a recent hematoma is found that measures 2.5 x 2.0 cm. The hemorrhage involves the region of the declive, folium and tubar. Smaller satellite contusions and hemorrhagic necrosis are scattered lateral to the large contusion of the superior surface of the cerebellum. Both cerebellar hemispheres are markedly swollen with flattened gyri and with a cerebellar pressure cone. Two small areas of hemorrhagic necrosis, each 3 mm in diameter, are present in the cortex of the herniated left cerebellar tonsil. The right cerebellar tonsil shows a single area of cortical hemorrhagic necrosis also 3 mm in diameter.

A elliptical groove over the superior surface of the anterior lobe of the cerebellum indicates upward herniation of these structures through the incisura of the tentorium cerebelli.

Horizontal sections of the cerebellum reveal the penetrating wound and the hemorrhage described above. These lesions have destroyed much of the cortex and subcortical white matter of the right cerebellar hemisphere, the dentate nuclei and probably the roof nuclei.

#### E. Brain Stem

The ventral surface of the pons and medulla is markedly flattened.

The periaqueductal gray matter contains multiple petechial hemorrhages extending over an area of 8 - 9 mm in width on the left side and about 5 mm on the right side. In sections above the pons the midbrain reveals several irregular hemorrhages within the tegmentum. The largest of these hemorrhages is slit-like and measures 5 x 1 mm in size and is situated in the left lateral tegmentum. Numerous petechial hemorrhages are found throughout both the tegmental and

ventral portions of the rostral 3/4 of the pons on multiple horizontal sections. Section through the medulla shows an area of hemorrhagic necrosis 4 x 3 mm in diameter located in the left inferior olive.

#### F. Ventricular System

The lateral and third ventricles are moderately narrowed in size. They contain a small amount of blood clot totaling about 6 cc. The source of the intraventricular hemorrhage is due to rupture into the right inferior horn of the hemorrhage of the right temporal lobe. The 4th ventricle also contains a small amount of fresh blood clot.

#### G. Spinal Canal and Spinal Cord

The foramen magnum and the upper cervical vertebrae are inspected and they show no abnormalities.

The bodies of the lower cervical, thoracic and upper lumbar vertebrae are removed in a column. After inspecting the spinal nerve roots, the cervical, thoracic and lumbar spinal cord is removed in toto.

A 41-cm portion of the spinal cord extending from the high cervical region into the lumbar region is examined. The leptomeninges are thin and transparent. The anterior spinal artery is thin-walled and shows no evidence of occlusion or laceration.

The posterior aspect of the spinal cord additionally reveals thin leptomeninges and normal distribution of vessels and nerve roots. There is no evidence of pathologic damage to the spinal cord. The subarachnoid space shows faint blood staining. Multiple transverse sections of the spinal cord and nerve roots show no gross lesions.

#### H. Pituitary Gland

The diaphragma sella and pituitary stalk are normal in appearance. The pituitary gland measures 1.1 x 0.8 x 0.5 cm. Section shows a pink homogeneous anterior lobe and a reddish gray posterior lobe. The bony structures forming and surrounding the pituitary fossa are all within normal limits.

## IV MICROSCOPIC FINDINGS

Sections confirmed all the lesions described at the gross examinations.

All tissue sections show congestion and some extravasation with occasional actual petechial hemorrhages, the latter is particularly noticeable in the thalami near the ventricular walls. A few mononuclear cells are present in the perivascular spaces. The ground substance of the cerebral cortex and centrum show fine vacuolations. In the occipital cortex, there is early status spongiosis, portions of which have a laminar distribution. Some nerve cells have pyknotic nuclei and homogenization of the cytoplasm, which, however, does show definite eosinophilia. The white matter of the frontal lobe shows occasional area of palor of staining. In the ventral pons, there is early necrosis in addition to the hemorrhages.



## V. CORRELATIVE PATHO-ANATOMIC DESCRIPTION AND INTERPRETATION OF LESIONS

The bullet entered the cranium through the upper portion of the right mastoid immediately behind the right pinna, one cm posterior to and at about the same level of the right external auditory meatus, directed 15 degrees anteriorly and slightly superiorly, shattering itself, causing a comminuted triangular fracture defect of the right petrous ridge, severing the superior petrosal sinus and lacerating the tentorium at its attachment to the ridge.

Thyright inferior temporal fusiform and hippocampal gyri, which rest immediately above the fractured petrous ridge, are contused and lacerated by bullet and bone fragments.

The cerebellum is immediately posterior to the petrous ridge beneath the tentorium and it is entered by bullet and bone fragments which are directed 45 degrees posteromedially and 30 degrees superiorly, producing a linear tract through the right dorsal portion of the cerebellar cortex and white matter and terminates in the superior vermis.

Preoperative and postmortem radiographs show metallic fragments in the defect of the mastoid and petrous portions of the right temporal bone, in the lacerated dura, and in the right temporal lobe and cerebellar lesions that are in juxtaposition to the involved temporal bone, thus confirming that these two lesions in the temporal lobe and cerebellum are primary bullet wounds.

The contusion of the right orbital gyri, with associated lacerated dura and fractured supraorbital plate, and contusion of right inferior occipital region are several centimeters away from the penetrating wounds and are interpreted as secondary to the sudden intracranial expansile and translational forces produced by the entrance of the bullet into the brain. The small contusion of the inferior temporal convolution of the opposite (left) hemisphere, hemorrhagic necrosis of left inferior olive and cerebellar tonsils, and epidural hemorrhage at C1 and C2 vertebral level are interpreted likewise as secondary to the sudden increase of intracranial pressure produced by the penetrating bullet. There are no metallic fragments in the vicinity of these lesions as shown by the radiographs.

Hemorrhage into the subdural and subarachnoid spaces and into the ventricles must have followed immediately after the initial injuries and the amount could have subsequently increased.

Edema of the brain and hemorrhages of the brain stem, due to compression and herniation, are almost inevitable delayed sequela of serious craniocerebral injuries.

## VI SUMMARY OF ANATOMIC PATHOLOGY

## A. Primary Lesions - Gunshot Wounds

1. Bone, dura and dural sinus
  - a. Penetration of right mastoid process
  - b. Fracture of right petrous ridge
  - c. Severance of right petrosal sinus
  - d. Metal fragments in right temporal bone
2. Cerebrum
  - a. Contusion-laceration and hemorrhage of right temporal lobe
  - b. Intraventricular hemorrhage due to above
  - c. Metal and bone fragments in right temporal lobe
3. Cerebellum
  - a. Hemorrhagic tract and cavity in right cerebellar hemisphere
  - b. Metal and bone fragments in right cerebellar hemisphere

## B. Immediate Secondary Lesions

1. Bone lesion
  - a. Fracture of right supraorbital plate
2. Meningeal lesions
  - a. Subdural hemorrhage
  - b. Subarachnoid hemorrhage
  - c. Laceration of right supraorbital dura
3. Cerebral lesions
  - a. Contusion-laceration of right orbital gyri
  - b. Contusion-laceration of right occipital lobe
  - c. Contusion of contralateral (left) inferior temporal gyrus
4. Cerebellum
  - a. Hemorrhagic necrosis of cerebellar tonsils
5. Brain stem
  - a. Hemorrhage in midbrain
  - b. Hemorrhagic necrosis of left inferior olive of medulla
6. Epidural hemorrhage of C1 and C2 vertebral level

## C. Surgical Procedures

1. Craniotomy, right temporo-occipital
2. Debridement

D. Late Secondary Lesions

1. Edema of brain and herniations
2. Subdural hemorrhage
3. Subarachnoid hemorrhage
4. Intracerebral and intraventricular hemorrhage
5. Hemorrhagic infarction of right temporal cortex
6. Intracerebellar and intraventricular hemorrhage
7. Petechial hemorrhages of thalami
8. Brain stem hemorrhage and early necrosis
9. Herniation of cerebellum through craniotomy wound
10. Early laminar necrosis of occipital lobe

ROUGH DRAFT

14

#68-5731  
ROBERT F. KENNEDY

VII FINAL DIAGNOSIS

AMJ:ATL  
9/26/68



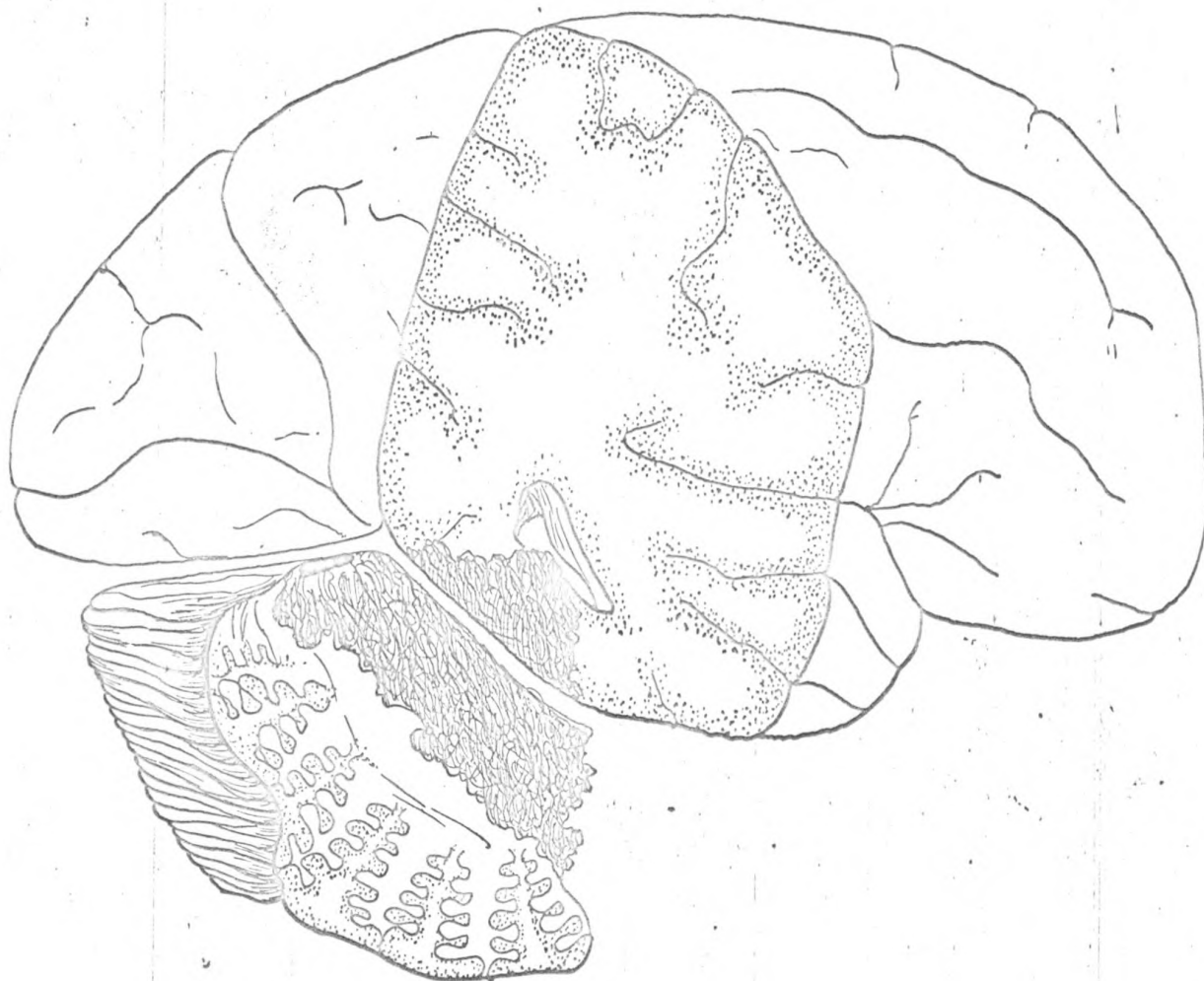


FIG. 1 POSTEROLATERAL VIEW OF A DISSECTION ILLUSTRATING THE EXTENT OF DAMAGE TO THE CEREBRUM AND CEREBELLUM. DARK OBJECT INDICATES RETAINED METALLIC FRAGMENT

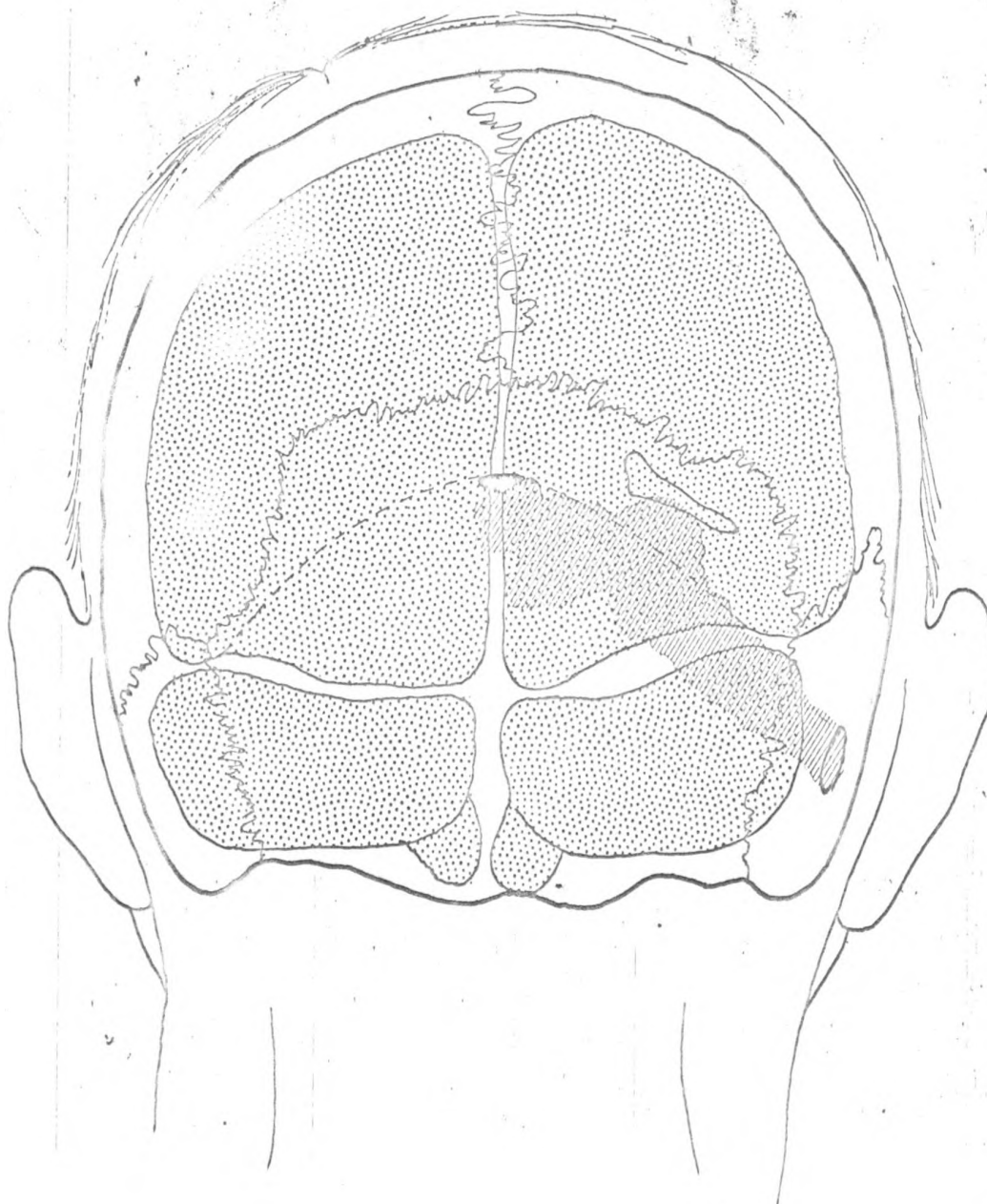


FIG. 2 POSTERIOR VIEW SHOWING RELATIONSHIP OF THE PENETRATING WOUND TO THE RAISED TENTORIUM (DOTTED LINE). DARK OBJECT IN MIDLINE INDICATES RETAINED METALLIC FRAGMENT.



FIG. 3 LATERAL VIEW ILLUSTRATING RELATIONSHIP OF  
PENETRATING WOUND TO THE MASTOID REGION  
AND THE BRAIN.

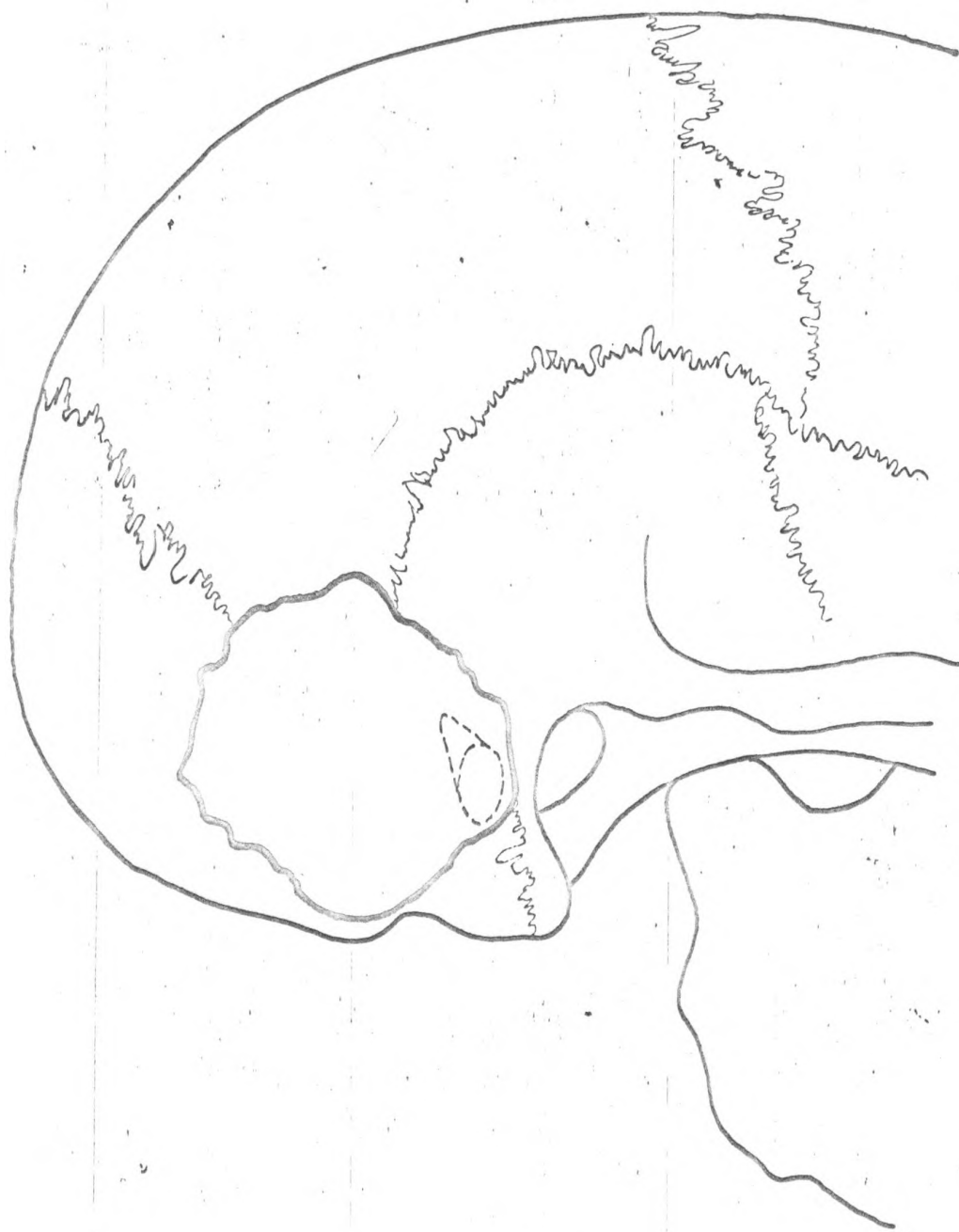

FIG. 4 DIAGRAM OF SKULL ILLUSTRATING LOCATION OF PENETRATING WOUND OF BONE (DOTTED LINES) AND THE CRANIOTOMY.



ENCLOSURE

(5) enclosures to Bureau  
to go with Los Angeles XXXXXXXXXX airtel  
dated 10/17/68, described as:  
178 photos of ballistic exam & autopsy of KENNEDY;  
1 RD copy composite gross protocol; 1 RD copy neuropathology report;  
1 RD copy descriptions of photos A1 thru B6, excluding B2; and  
1 RD copy descriptions of photos CL thru C32  
Re: KENSALT  
Los Angeles file number 56-156  
file number 62-587

See Airtel 2/5/69  
KENSALT Re: 141, 154, 160  
161, 164, 165,  
166, 167, 170

6/6/68

SAC, LA

KENSALT

ENCL ARE 14 PHOTOS OF ROBERT F. KENNEDY  
DURING POSTMORTEM EXAM & CORONER'S AUTOPSY.  
SUBMITTED FOR INFO ONLY. OFFICIAL COLORED  
PHOTOS BEING DEVELOPED & WILL BE MADE  
AVAIL.

(P)



6/6/68

AIRTEL

AIR MAIL - REGISTERED

TO: DIRECTOR, FBI

ATTN: ASSISTANT TO THE  
DIRECTOR CARTHA D.  
DE LOACH

FROM: SAC, LOS ANGELES (56-156)

RE: KENSALT

Enclosed are 14 photographs made of ROBERT F. KENNEDY during the postmortem examination and coroner's autopsy.

The enclosed photographs were made by CHARLES COLLIER, Scientific Investigations Division, Photography Laboratory, Los Angeles Police Department.

The enclosed photographs are submitted for information only. Official colored photographs are being developed and will be made available.

4 - Bureau (Encls. 14) (RM)  
3 - Los Angeles

SCM/kaf  
(7)



6/6/68

AIRTEL

AIR MAIL - REGISTERED

TO: DIRECTOR, FBI

ATTN: ASSISTANT TO THE  
DIRECTOR CARHA D.  
DE LOACH

FROM: SAC, LOS ANGELES (56-156)

RE: KENSALT

Enclosed are 14 photographs made of ROBERT F. KENNEDY during the postmortem examination and coroner's autopsy.

The enclosed photographs were made by CHARLES COLLIER, Scientific Investigations Division, Photography Laboratory, Los Angeles Police Department.

The enclosed photographs are submitted for information only. Official colored photographs are being developed and will be made available.

4 - Bureau (Encls. 14) (RM)  
3 - Los Angeles

SCM/kaf  
(7)



<sup>o</sup>  
~~X~~  
Kennedy, Robert F.  
Autopsy Report - Robert F. Kennedy

KENNEDY, ROBERT F.

OC



**This marker identifies the original location of autopsy photographs, which, due to privacy concerns and out of respect for the Kennedy family, are available only onsite at the National Archives in College Park, Maryland.**